

Principal Testicular Diseases in *Bos* sp. Bulls

Jair Millán-Orozco¹, Jersson Millán-Orozco¹, Luís Saavedra-Jiménez², Jahdai Hernández-Morales² and María Bottini-Luzardo^{2,*}

¹Laboratorio de Anatomía, Departamento de Ciencias Médico Veterinarias, División Regional de Ciencia Animal, Universidad Autónoma Agraria Antonio Narro (UAAAN), Torreón, México

²Facultad de Medicina Veterinaria y Zootecnia No. 2, Universidad Autónoma de Guerrero, Cuajinicuilapa, México

*Corresponding author: 17906@uagro.mx

Abstract

The testicles are the fundamental functional unit of the male mammal reproductive system. They are endocrine organs, whose main product is testosterone and are where spermatogenesis occurs. In *Bos* sp. bulls, testicular function is vital to successful breeding. Despite their location in the inguinal area, they can suffer damage from trauma. They are also susceptible to damage from bacteria, viruses, and parasites, which can find the testicles to be an ideal developmental environment. Hyper and hypo nutrition can have negative effects on the testicles, the degree of reversibility of which depends on animal age and exposure time. Genetic disorders affecting the testicles can prevent bulls from performing as sires due to changes in physiology that impact reproductive function, with the added risk of trait heritability. Regardless of their origin, testicular diseases are usually not detected due to a lack of knowledge of testicular pathologies and delays in andrological evaluations.

Keywords: Reproduction, Testosterone, Males, Spermatozoids, Dysfunction

Cite this Article as: Millán-Orozco J, Millán-Orozco J, Saavedra-Jiménez L, Hernández-Morales J and Bottini-Luzardo M, 2025. Principal testicular diseases in *Bos* sp. bulls. In: Kausar R, Nisa ZU, Jamil M and Bashir I (eds), Integrated Health and Sustainability: Plants, Wildlife, and Genetic Resilience. Unique Scientific Publishers, Faisalabad, Pakistan, pp: 116-124. <https://doi.org/10.47278/book.HH/2025.70>



A Publication of
Unique Scientific
Publishers

Chapter No:
25-017

Received: 15-Feb-2025
Revised: 12-March-2025
Accepted: 18-May-2025

Introduction

In production systems, livestock dedicated to breeding, it represents half of the herd, since it increases conception rates. Butler et al. (2020) point out that bull fertility has been correlated with aspects such as daily weight gain, heifer gestation and interval between calvings; that is, it also has effects on productive parameters. Despite its importance, the evaluation of sires has received less attention than that of females.

The testicles are the endocrine organs responsible for spermatogenesis. They can suffer from pathologies of genetic, bacterial, viral or even parasitic origin, or suffer trauma that compromises their functionality. Studies carried out on slaughter animals have reported between 40 and 70% of animals with testicular pathologies (Kouamo & Egbe Eta, 2021; Diaz-Miranda et al., 2024), most of which were not detected, causing a decrease in the reproduction and productivity of the herd.

1. Genetic Testicular Diseases

i. Testicular Hypoplasia

Characterized by incomplete development of the germinal epithelium of the seminiferous tubules, this disorder leads to decreases in sperm concentration and increases in morphological alterations, as well as azoospermia (De Lima Silva et al., 2022). It can occur unilaterally or bilaterally and can be total or partial. When of genetic origin, it arises from changes in cell chromosome count due to loss or duplication (aneuploidy) of genetic material, and expression of an autosomal recessive gene that interferes with spermatogenesis (Salvador & Salvador, 2021). Visual diagnosis is possible since testicular hypoplasia causes reduced testicle size.

Genetic analysis has determined that this trait has 0.16 heritability, and negative genetic correlations with scrotal circumference (-0.53), the selection at weaning index (-0.32) and the combined weaning and year index (-0.36) (Neves et al., 2019). Expression of testicular hypoplasia may be related to genes associated with steroid metabolism and synthesis, cell survival, spermatogenesis and sperm motility.

ii. Cryptorchidism

Cryptorchidism is the failure of one or both testicles to descend into the scrotum at the normal developmental moment (Ayodeji & Suwaiba, 2013). Although considered heritable, no DNA-based tests have been found for this pathology in cattle, but some genes that code for proteins involved in testicle formation and maturation may contribute to its occurrence. Alterations in genes that regulate testosterone production, or responses to it, may also be related to this pathology. Finally, abnormalities in genes controlling development of the inguinal canal can also prevent testicular descent (Ahmet et al., 2019). Diagnosis is via palpation of the scrotum and inguinal area.

iii. Gonadal Dysgenesis

Gonadal dysgenesis is used to describe any congenital developmental disorder of the reproductive system in either males or females (Berry

et al., 2022), in males the testicles do not develop properly. It is a complex condition resulting from a combination of genetic, chromosomal, and environmental factors. In cattle, as well as other animals, it can be associated with chromosomal abnormalities, such as Turner syndrome (XO) or Klinefelter syndrome (XXY), which affect normal gonad development gonads and, therefore, reproductive function (Gómez et al. 2020). It is also associated with genetic mutations and alterations in genes specific to gonadal development, such as mutations in the SRY gene, essential in determining male sex (Berry et al., 2022). Gonadal dysgenesis has a significant impact on reproductive health in affected animals, with variable results including infertility, abnormalities in sexual development, and hormonal problems.

iv. Klinefelter Syndrome

This syndrome is widely reported in many of the species including livestock. As in other animals, in cattle, this syndrome is characterized by the presence of an additional sex chromosome. There are cases of bulls with a 61, XXY karyotype, that is, with an additional X chromosome. Bulls with this syndrome exhibit bilateral testicular hypoplasia, degenerated seminiferous tubules, and incomplete development of reproductive organs leading to infertility to complete sterility are among the major consequences of the syndrome (Niranjan et al., 2024).

v. Anorchia

Anorchia is the congenital absence of one or both testicles (unilateral or bilateral), related to a lack of development in one or both testicles. It is rarely reported in bulls. Diagnosis is by physical examination and, in some cases, imaging studies or hormonal analysis to evaluate testicular function. Its identification is important in bulls to prevent the use of affected individuals in breeding programs (Cicirelli et al., 2023). The specific cause of anorchia in bulls is not known but may be related to genetic factors and therefore be hereditary.

vi. Segmental Aplasia of the Structures Originating in the Mesonephric duct

This is the absence or incomplete development of certain elements of the male reproductive system. It has multiple causes, including genetic factors, suggesting it may be hereditary, possibly with a recessive transmission pattern. Among its manifestations are reproductive anomalies resulting from the absence or incorrect development of reproductive structures such as epididymis and vas deferens, causing an inability to effectively transport sperm (Williams et al., 2010).

2. Testicular Diseases caused by Parasites

i. Trypanosomiasis caused by *Trypanosoma vivax* and *Trypanosoma congolense*

Initial research into the effects of trypanosomiasis caused by *T. vivax* (Figure 1) and *T. congolense* at the reproductive level identified a decrease in sperm concentration and ejaculate volume, as well as an increase in sperm cell abnormalities (Ali et al., 2021). In bulls, chronic trypanosomiasis due to *T. vivax* and *T. congolense* causes a considerable increase in sperm morphological abnormalities in the acrosome, head (pyriform heads, very narrow heads, and separated heads), and proximal and distal cytoplasmic droplets, in addition to increasing abnormalities in the middle portion and tail of spermatozoa in all infected individuals (Amin et al., 2020)

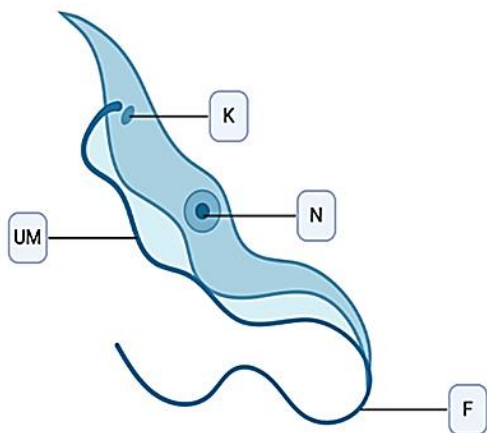


Fig. 1: Schematic of *T. vivax* trypomastigote (18-26µm long) with its rounded posterior end; its nucleus in the central part (N); with its slightly undulating membrane (UM); with its free flagellum at the anterior end (F); with a large terminal kinetoplast (K), essentially monomorphic (Retrieved from Biorender).

In other studies, infected bulls exhibited higher ejaculate volume, and slightly lower libido, sexual vigor, sperm concentration and motility than uninfected bulls (Bittar et al., 2015). The febrile state produced by *T. vivax* generates conditions that contribute to lower reproductive and sexual development in infected animals. None of the infected bulls were suitable breeders since their semen characteristics were poor, resulting in both oligospermia and azoospermia (Betancour Hurtado et al., 2016). Diagnosis of trypanosomiasis is done by blood smear and morphometry to identify and/or differentiate the infecting *Trypanosoma* species. In addition, PCR and indirect immunofluorescence assay (IFA) can be used (Da Silva et al., 2022). Trypanosomiasis in cattle can be treated with drugs, including diminazene acetate and isometamidium chloride; the latter prevents infection for two to three months (Giordani et al., 2016).

ii. Neosporosis caused by *Neospora caninum*

Few studies have identified a direct effect of infection with the protozoan *N. caninum* (Figure 2) on testicular structure or activity. However, naturally-infected bulls have a smaller testicular circumference than uninfected bulls (Bahrami et al., 2017). Infection has also been reported to cause lower testosterone plasma concentrations compared to a control group. This is caused by the effects of parasite antigens on testicular function through interaction with the hypothalamic-pituitary-adrenal axis, which interrupts thyroid function and produces hypogonadism. Infected animals exhibit an adaptive response as well as oxidative stress and hormonal changes in the testicles due to parasite presence (Bahrami et al., 2018). Detection of *N. caninum* is normally done with an ELISA test, although PCR is also effective (Morales et al., 2001). No treatment exists for neosporosis, meaning preventive measures are the only way to avoid this disease (Santana et al., 2010; López-Alvarez et al., 2024).

iii. Trichomonosis caused by *Tritrichomonas foetus*

Trichomonas foetus (Figure 3) infection in cows can lead to abortions and infertility. In bulls, infection can cause tropism via agglutination of sperm, as well as a marked decrease in sperm motility due to phagocytosis produced by the parasite (Ribeiro et al., 2010). Adhesion of this protozoa to sperm occurs mainly in the flagellum and head (Tung & Suarez, 2021).

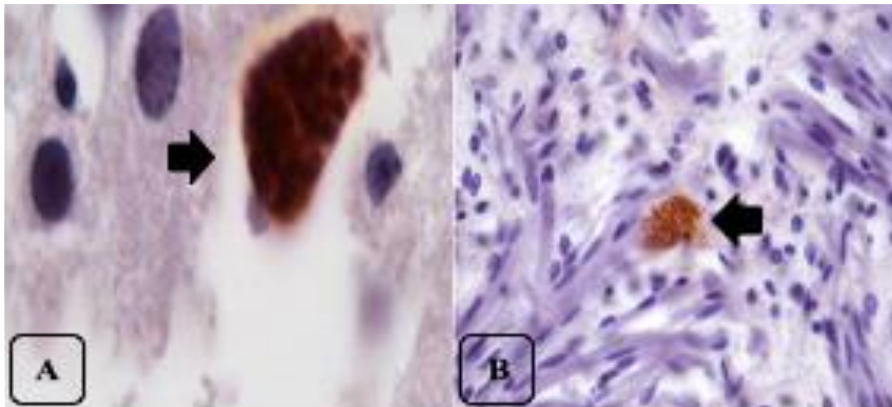


Fig. 2: *Neospora caninum* tachyzoites (black arrows) identified by immunohistochemistry in cerebral cortex (A) and the tongue musculature (B) in aborted fetuses. (Image adapted from Orlando et al., 2013) (The use of the photographs used for this figure was authorized by the authors).

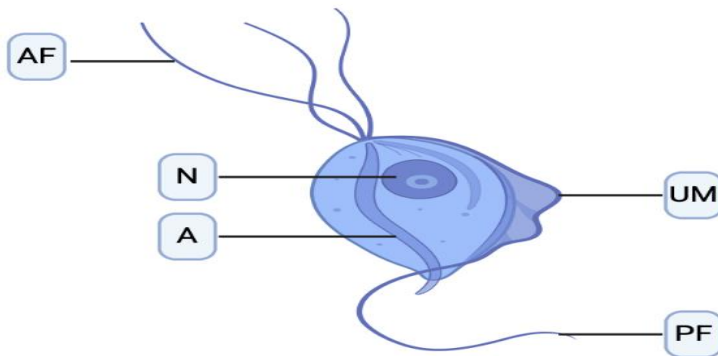


Fig. 3: Schematic of *Tritrichomonas foetus* trophozoite (10-25µm) with its three anterior flagella (AF); with nucleus in the anterior part of the body (N); with a trailing flagellum that extends beyond the undulating membrane (UM); with a longitudinal axostyle (A); with a posterior flagellum (PF) (Retrieved from Biorender).

An *in vitro* study done in Brazil focused on the interaction between *T. foetus* infection and sperm in Holstein-Friesian bulls and evaluated the effect of the protozoan's secretions on reproductive cells. Agglutination occurred in infected bulls, as well as a progressive decrease in sperm motility. Cysteine proteinases were constantly expressed, generating sperm cytotoxicity from extracellular products consistent with an increase in pathogenesis and infertility in infected bulls (Ribeiro et al., 2010). *T. foetus* infection can be confirmed by analyzing preputial secretions and even semen samples with scanning electron microscopy.

iv. Besnoitiosis caused by *Besnoitia besnoiti*

Besnoitia besnoiti is a cyst-forming, apicomplexan protozoan parasite (Figure 4) which causes bovine besnoitiosis. It has been reported in several countries and on different continents. Research using *Bos indicus* and *Bos taurus* bulls found that it manifests clinically as macroscopic lesions on the skin of the scrotum; various degrees of alopecia, thickening, and crystallization; nodules in the vaginal tunica and albuginea; and degeneration, hardening and fibrosis of the testicular parenchyma (Esteban-Gil et al., 2016) as well as marked testicular edema and congestion, and petechiae in the tunica albuginea of the epididymides (Dubey et al., 2013).

The disease can be diagnosed at a subclinical stage using microscopic observation to identify obvious symptoms of chronic subclinical disease such as vasculitis of the reproductive tract, mainly in the testicles, epididymis, vas deferens, and bulbourethral glands, with the presence of granulomas; as well as vascular damage, inflammation and edema in the scrotum, testicular parenchyma, epididymis, and pampiniform plexus. Chronic *B. besnoiti* infections may exhibit hyperkeratosis, acanthosis, and marked diffuse fibroplasia in the scrotum dermis; in addition to an intense inflammatory infiltration in the testicular parenchyma accompanied by germline atrophy in the seminiferous tubules with germ cell disappearance (Diezma-Díaz et al., 2020). *B. besnoiti* infection can be identified by the presence of scleroconjunctival cysts. Histology is highly effective for observing lesions in skin samples from animals with chronic subclinical infections. No treatment is currently available for *B. besnoiti* (Diezma-Díaz et al., 2018).

3. Bacterial Testicular Diseases

i. Brucellosis Orchiepididymitis

Brucellosis is a bacterial and zoonotic disease caused mainly by *Brucella abortus*. This bacterium enters the body through the oral or nasal mucosa, spreads via the lymphatic system and generates bacteremia, lodging in the testicles and epididymides because they contain erythritol, a sugar that favors *B. abortus* proliferation (Fiebig et al., 2021).

The infection causes chronic orchitis, generally unilateral, although in severe cases it can become bilateral and lead to total testicular necrosis, atrophy, and loss of reproductive function. Other signs of infection include epididymitis, ampulitis and seminal vesiculitis, which

compromise semen quality and lead to partial or total infertility (Poester et al., 2013). Some infected bulls remain asymptomatic, acting as carriers and silently disseminating *B. abortus* in a herd. The disease is detected by serological tests such as the agglutination test and ELISA. Contagion can be limited through management practices such as vaccination, eliminating contact with contaminated materials and animals, and most effective, culling infected animals.

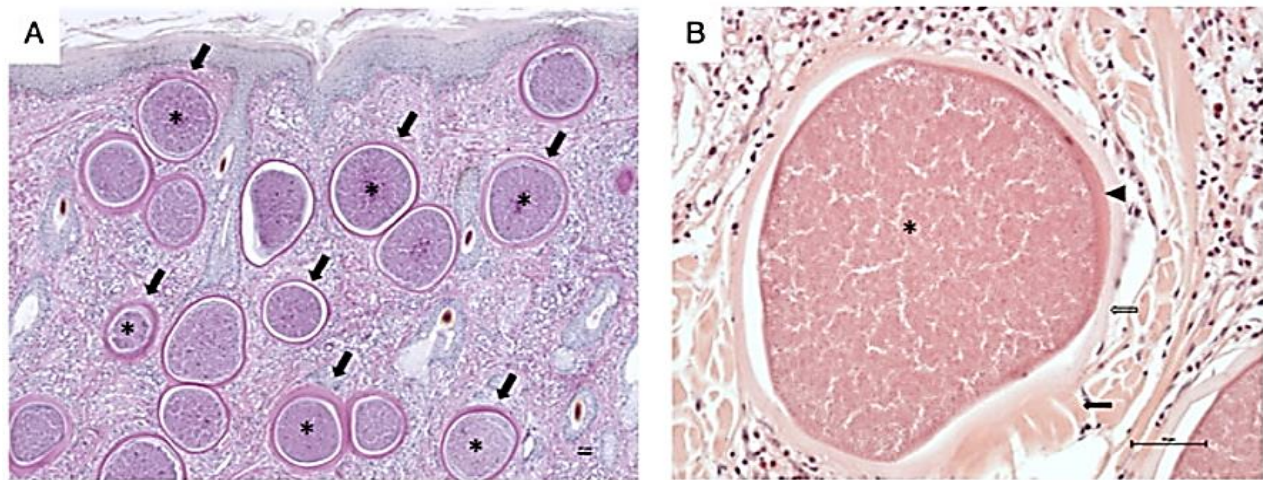


Fig. 4: Histological sections of skin from cattle infected with *Besnoitia besnoiti* (scale bar = 50µm). A) Mature *Besnoitia besnoiti* cyst within the dermis (Schiff's periodic acid stain, 40X magnification). B) Mature *Besnoitia besnoiti* cyst with three well-defined walls, composed of an outer wall (black arrow), a middle wall (white arrow), and an inner wall (arrowhead), (Haematoxylin-Eosin stain, 200X magnification). Images obtained and modified from Zhou et al., 2020 (The use of the photographs used for this figure was authorized by the journal as it is an open access publication).

ii. Testicular Tuberculosis

Testicular tuberculosis is an extrapulmonary manifestation of *Mycobacterium bovis*, a bacteria responsible for tuberculosis, another zoonotic disease. Chronic *M. bovis* infection in the testicles facilitates pathogen excretion through the semen, which transmits it within a herd. Clinical signs include orchitis, scrotal pain, and epididymal inflammation, frequently accompanied by the formation of abscesses or fistulas with drainage of purulent material, which leads to progressive tissue damage, caseous necrosis, fibrosis, and atrophy. General animal health can also be affected in the form of systemic signs such as fever, weight loss, and lethargy (Grandjean-Lapierre et al., 2018).

Diagnosis of testicular tuberculosis should include histopathological analysis, bacterial cultures, molecular tests such as PCR, *rpoB* gene sequencing, and mass spectrometry (Amorim et al., 2022). Effective control requires surveillance, early diagnosis, and strict preventive measures, including the elimination of infected animals and proper handling of contaminated products.

iii. Testicular Actinomycosis

Actinomycosis is caused by infection with the bacteria *Actinomyces israelii*. This pathogen most frequently affects the genitourinary organs, reaching the testicles by hematogenous or lymphatic dissemination. In most cases, testicular infection is secondary to a primary infection in the abdominal, thoracic or cervical cavities. Once *A. israelii* reaches the testicles, it induces a chronic inflammatory response characterized by formation of granulomas with central necrosis and the presence of distinctive sulfur granules. The latter, consisting of bacterial conglomerates surrounded by a protein and polysaccharide matrix, are essential for definitive diagnosis (Das et al., 2022).

Histologically, lesions exhibit basophilic granules with central bacterial filaments surrounded by “club”-shaped eosinophilic material, a pathognomonic feature of actinomycosis. Clinical signs include testicular swelling, pain, and enlargement, either unilateral or bilateral, with purulent drainage in more advanced cases. Systemic symptoms such as fever, weight loss, and malaise may also occur. Definitive diagnosis of testicular actinomycosis is by histopathology, in which sulfur granules and bacterial filaments are key features, and by anaerobic culture (Veenakumari & Sridevi, 2017).

Treatment is via high doses of penicillin G administered for prolonged periods, followed by oral amoxicillin. In complicated cases, such as the presence of large abscesses or advanced fibrosis, surgical intervention, such as drainage or orchiectomy, may be necessary. Prevention includes careful management of trauma and prompt attention to local infections, which can significantly reduce its incidence. Early diagnosis, based on identification of sulfur granules and isolation of *A. israelii*, is essential to avoid unnecessary surgical interventions and ensure adequate treatment (Gajdács & Urbán, 2020)

iv. Orchiepididymitis due to *Escherichia coli*

The gram-negative bacterium *E. coli* is a normal element in mammal intestinal flora but can become pathogenic under certain conditions. In cattle, testicular infection by *E. coli* generally occurs by ascending dissemination from the urinary tract or, less frequently, by hematogenous dissemination from a distant infection locus. The pathogenic mechanism begins when *E. coli* enters testicular tissue, where it triggers an acute inflammatory response characterized by leukocyte infiltration and abscess formation in one or both testicles, accompanied by pain and fever

as well as loss of appetite (Givens, 2018). Bacterial proliferation causes tissue necrosis, leading to the formation of fistulas and purulent cavities. As the infection progresses, the affected tissue is replaced by fibrous tissue due to chronic inflammation, which affects testicular function and, consequently, semen quality. Sperm motility and viability are impaired by persistent inflammation in conjunction with oxidative stress and direct damage to the sperm membrane mediated by bacterial adhesins, leading to infertility in severe cases (Ďuračka et al., 2021). Diagnosis of testicular *E. coli* infection combines scrotal ultrasound to identify structural alterations such as abscesses, urinalysis to confirm pyuria associated with ascending bacterial infection, and definitive confirmation through bacterial culture, which also quantifies antimicrobial sensitivity, a crucial datum for determining treatment. Infection management usually requires long-term administration of broad-spectrum antibiotics (e.g., cephalosporins or enrofloxacin). In severe cases with extensive testicular damage or significant abscesses, orchiectomy of the affected testicle may be necessary to prevent extensive infection spread and preserve reproductive function in the contralateral testicle (Ivanov et al., 2021).

4. Viral-origin Diseases

i. Bovine Viral Diarrhea (BVD)

The BVD virus is a pestivirus, not usually found in bull testicles. When present it can be released via semen, transmitting the virus to cows receiving contaminated semen through natural or artificial insemination. Since the testicles are not known to react to BVD infection, serological tests are required prior to using a sire for mating or service (Newcomer et al., 2014). Vaccination effectively prevents BVD, highlighting the need to keep herds vaccinations up to date and regularly check for symptoms.

ii. Bovine Herpes

This disease is caused by the herpes virus, belonging to the *herpesviridae* family. There are several serotypes distributed worldwide which affect bovine reproduction. It is largely disseminated by the use of contaminated bovine semen in artificial insemination (Givens, 2018). In the testicles, the virus causes transitory hyperemia, edema, and subsequent decreases in sperm concentration. However, the latter effect is intermittent, meaning that, even after extraction and freezing, infected sperm can still transmit the virus (Morán et al., 2015; Pichardo et al., 2023). Effective diagnosis is by PCR, although it can also be diagnosed by ELISA, immunofluorescence, and immunoperoxidase techniques. Prevention involves vaccination and culling of infected animals (Souza et al., 2018).

iii. Bluetongue Virus (BTV)

An arbovirus common in ruminants, BTV causes physical discomfort and signs such as fever, arthritis, encephalitis, and hemorrhages, which can decrease sire libido and ability to mount. In the testicles, BTV replicates in the peritubular endothelial cells, affecting the Leydig cells, which reduces testosterone biosynthesis and Sertoli cell count. The testicular parenchyma consequently suffers degeneration, leading to decreased spermatogenesis and low sperm concentration (Puggioni et al., 2018). Vaccines effectively prevent contagion, and insecticides can control arthropod vectors.

iv. Bovine Leukosis Virus (BLV)

A globally-distributed ribovirus, BLV can be acquired through intake of contaminated milk or semen, or wounds in the mucous membranes. Research on BLV's effects on sperm quality is contradictory, with some reports indicating it lowers sperm concentration and increases the occurrence of malformations (Ferrer et al., 2024) while others found no effect on sperm quality (Pichardo-Matamoros et al., 2023). It is generally accepted that BLV has no negative effects on testicular tissue, possibly due to the presence of leukemia inhibitory factors in the blood-testicle barrier (Rodriguez et al., 2011). No vaccine or treatment yet exists for BLV, so preventive measures are the sole method against it infecting a herd.

5. Diet-related Testicular Diseases

i. Energy Intake

Within the testicle, the Leydig and Sertoli cells are the main structures of the seminiferous tubules. Sertoli cells are responsible for nourishing sperm from early development until their exit into epididymis. Nutritional factors can negatively affect the function of Sertoli cells. A balanced diet that meets the nutritional requirements of bulls during early growth stages favors testicular structure development and initiation of spermatogenesis. In contrast, a hyper-energetic diet can trigger inflammatory processes, the presence of fibrous tissue, and cytoplasm atrophy and vacuolization, causing spermatogenesis disorders (Harrison et al., 2022). In addition, the testicles are affected when an animal is being finished, which can prevent testicle temperature regulation, consequently harming spermatogenesis and overall seminal quality.

ii. Minerals

Mineral nutrition influences cellular activity, including reproductive cells. Some minerals have a direct effect on testicular growth. For example, zinc deficiency can negatively affect pituitary hormone synthesis and secretion patterns, causing potentially irreversible delays in testicular growth. Severe selenium deficiency has been linked to seminiferous tubule atrophy and hypogonadism at any age (Silva et al., 2019).

iii. Proteins

An integral part of animal cellular structure, proteins are necessary for the growth of striated and smooth muscles, such as testicular tissues. Some proteins are associated with fertility and their presence correlates to testicle size and temperature (Jibril et al., 2011). For example, protein-deficient diets can cause testicular atrophy in mice. Ruminants cover some of their protein requirements by degrading microbial protein. However, this cannot completely meet their protein needs, and they require supplements to prevent delays in body development. Any developmental delays will be reflected in testicular development, as reported in a study showing seminiferous tubule atrophy in pubescent bulls

fed a low protein diet. However, hyperproteinaceous diets can cause testicular hypoplasia. In cattle, optimal testicular development is attained with a 12 to 14% CP diet (Rekwot et al., 1987).

iv. Phytoestrogen Exposure in Forage and feed

Phytoestrogens are compounds in plants. Feed ingredients such as soy, as well as other forages, contain phytoestrogens which can bind to estrogen receptors and function as weak estrogens in the organism. Excessive phytoestrogen exposure can interfere with testosterone production due to a negative effect on Leydig cells Leydig (Rahman et al., 2022). High doses and long exposure times can lead to permanent damage, while low doses can positively affect testicle development in pubescent animals (Yurrita, 2016).

v. Dietary Heavy Metals

Due to environmental pollution, some feed ingredients may contain heavy metals such as lead, cadmium, or arsenic. Heavy metal accumulation can cause testicular toxicity, interfering with testicular cell function and generating oxidative stress. A principal negative effect is disruption of testicular endocrine function, causing damage such as cytoplasm vacuolization in Leydig and Sertoli cells and degeneration of the germinal epithelium, as well as negatively affecting testosterone production, and, consequently, spermatogenesis (Chand et al., 2019, Gonzaga-Aivar et al., 2021). Summarizes the effects of nutrition on testicular health shown in Table 1.

Table 1: Main effects of diet on the testicle

Element	Effects of diet	References
Loss energy	Low testicular development and spermatoc concentration	
High energy		
Energy	Testicular inflammation, sperm disorders	(Harrison et al., 2022)
Mineral deficiency	Low sperm concentration and malformations, testicular hypoplasia	(Silva et al. 2019)
Protein, loss, or high energy	Testicular hypoplasia	(Jibril et al., 2011)
Phytoestrogen	Low testosterone concentration, low fertility.	(Rahman et al., 2022)
Heavy metals	Spermatoc malformation, parenchyma degeneration	(Chand et al., 2019; Gonzaga-Aivar et al. 2021)

6. Idiopathic or Multi-Source Testicular Pathogens

Testicular parenchyma degeneration is diffuse degradative changes in the testicular parenchyma caused by permanent damage to the seminiferous tubules resulting in fibroids. It is the consequence of various bacterial and viral diseases, and even genetics (Koziol & Palmer 2023). Some testicular parenchyma cases can be due to degeneration of the parenchyma from trauma, insect bites, exposure to high temperatures, weight loss, and even excessive weight gain, which prevents thermoregulation because of lipid deposits in the testicles. Age can also increase the probability of a bull developing parenchymal degeneration with degenerated testicles being more frequent in bulls after eight years of age.

Testicular hematoma frequencies as high as 2.1% have been reported; many may be due to trauma, while others were idiopathic in origin. Orchitis, inflammation of the testicles, can also result from trauma of the testicles. Histological signs of chronic orchitis include absence of germinal epithelium, thinning of the basal membrane, narrowing of the tubular lumen and Leydig and Sertoli cell dysfunction (Uyar et al., 2019).

Testicular microlithiasis, stones in the testicles, is categorized on a scale of 1 to 3 of increasing severity. At grades of 2 to 3, testicular health is compromised, leading to lower sperm concentrations due to seminiferous tubule obstruction, and, possibly, Sertoli cell displacement. As in other species in which it occurs, testicular microlithiasis in bulls is of unknown origin (Medel-Martínez et al., 2023).

Conclusion

The testicles are the most important endocrine and reproductive structure in bulls. They are susceptible to various genetic and viral diseases, but those of bacterial and parasitic origin are more common. This is particularly because testicles provide an ideal environment for microorganism development. Rather than treatment, prevention is the most effective way to control testicular disease incidence. In the case of genetic disorders, culling of affected bulls is the most effective approach. Maintaining a balanced diet and average body condition is another effective preventive strategy. Excessively low or high body conditions should be avoided to avoid negative effects from excess or deficient dietary fat or protein. Feed and its ingredients should also be monitored to detect the presence of heavy metals and bacteria. Finally, periodic detailed evaluations of sires allow for timely and effective implementation of measures to control or treat diseases affecting the testicles.

References

- Ahmet, U., Uslu, B.A. & Yurdakul, I. (2019). Evaluation on the histopathology of testes anomalies in the bulls slaughtered at the City of Van. *Dicle Üniversitesi Veteriner Fakültesi Dergisi*, 12(1), 30-36.
- Ali, A., Derar, D. R., & Almundarij, T. I. (2021). Aetiological analysis and diagnosis of reproductive disorders in male dromedary camels. *Reproduction in Domestic Animals*, 56(10), 1267-1273.
- Amin, Y. A., Noseer, E. A., Fouad, S. S., Ali, R. A., & Mahmoud, H. Y. (2020). Changes of reproductive indices of the testis due to Trypanosoma evansi infection in dromedary bulls (Camelus dromedarius): semen picture, hormonal profile, histopathology, oxidative parameters, and hematobiochemical profile. *Journal of Advanced Veterinary and Animal Research*, 7(3), 537.
- Amorim, J. Q., Santos, B. R., Fehlberg, H. F., Silva, A. V., Ferreira, F. F., Costa, J. N. & Alzamora Filho, F. (2022). Isolation and molecular identification of Mycobacterium bovis in tissue lesions of cattle slaughtered in slaughterhouses located in the State of Ceará. *Arquivo*

- Brasileiro de Medicina Veterinária e Zootecnia*, 74(2), 338-344.
- Ayodeji, A. A. & Suwaiba, W. (2013). Cryptorchidism among indige-nous breeds of bulls in a semi-arid region of Nigeria. *Macedonian Veterinary Review*, 36(2), 123-128.
- Bahrami, S., Hamidinejat, H., Fatemi-Tabatabaei, S.R. & Sardarifar, S. (2017). Effect on natural neosporosis on Bull sperm quality. *Tropical Animal Health and Production*. <https://doi.org/10.1007/s11250-017-1403-8>.
- Bahrami, S., Reza Alborzi, A., Gooraninejad, S. & Bakrayi, O. (2018). Effect of natural neosporosis on levels of testosterone and thyroid hormones in Bulls. *Journal of the Hellenic Veterinary Medical Society*, 69, 984-990.
- Berry, D. P., Herman, E. K., Carthy, T. R., Jennings, R., Bandi-Kenari, N., O'Connor, R. E., Mee, J. F., O'Donovan, J., Matthews, D. & Stothard, P. (2022). Characterisation of eight cattle with Swyer syndrome by whole-genome sequencing. *Animal Genetics*, 54(2), 93-103. <https://doi.org/10.1111/age.13280>
- Betancour Hurtado, O. J., Jimenez Castro, P. D. & Giraldo-Ríos, C. (2016). Reproductive failures associated with *Trypanosoma (Duttonella) vivax*. REVIEW. *Veterinary Parasitology*, 229, 54-59.
- Bittar, J.F.F., Bassi, P.B., Moura, D.M., Garcia, G.C., Martins-Filho, O.A., Vasconcelos, A. B., Costa-Silva, M. F., Barbosa, C.P., Araújo, M. S.S. & Bittar, E.R. (2015). Evaluation of parameters related to libido and semen quality in Zebu bulls naturally infected with *Trypanosoma vivax*. *BMC Veterinary Research*, 11, 261. <https://doi.org/10.1186/s12917-015-0571-x>.
- Butler, M.L., Bormann, J.M., Weaber, R.L., Grieger, D.M. & Rolf, M.M. (2020). Selection for bull fertility: a review. *Translational Animal Science*, 4, 423-441. <https://doi.org/10.1093/tas/txz174>
- Cicirelli, V., Burgio, M., Mrenoshki, D., Cseh, S., Aiudi, G. & Lacalandra, G M. (2023). Update on canine anorchia: a review. *Veterinary Medicine and Science*, 9, 600-603.
- Chand, N., Tyagy, S., Prasad, R., Dutta, D., Sirohi, A.S., Sharma, A. & Tyagi, R. (2019). Effect of heavy metals on oxidative markers and semen quality parameters in HF crossbred bulls. *Indian Journal of Animal Science*, 89(6), 632-636.
- Das, T., Das, N.K., Mohapatra, S., Pathak, M., Chavan, A.S., Sahoo, M., Rani, H.B. & Kumar, G.S. (2022). A rare case report of actinomycotic scrotal granuloma in cattle. *Indian Journal of Veterinary Pathology*, 46(2), 167-169.
- Da Silva, A. S., Molosse, V. L., Deolindo, G. L., Cecere, B. G., Vitt, M. G., Nascimento, L. F. N., das Neves, G. B., Sartor, J., Sortori, V. H., Baldissera, M. D. & Miletti, L.C. (2022). *Trypanosoma vivax* infection in dairy cattle: Parasitological and serological diagnosis and its relationship with the percentage of red blood cells. *Microbial Pathogenesis*, 166, 105495.
- De Lima Silva, T., Gondro, C., de Souza Fonseca, P.A., Alves da Silva, D., Vargas, G., de Rezendes Neves, H.H. & Caravilho Filho, I. (2022). Testicular hipoplasia in Nelore Cattle: Genetic análisis and functional analysis of genome-wide association study results. *Journal of Animal Breeding and Genetics*, 140 (2), 185-187 <https://doi.org/10.1111/jbg.12747>
- Diaz-Miranda, E.A, Penitente-Filho, J.M., Gomez-Leon, V.E., Miranda Neto, T., Facioni Guimarães, S., Broch Siquiera, J. & Domingos Guimarães, J. (2024). Selection based on the breeding soundness evaluation is associated with the improvement of the reproductive quality of young Nelore bulls. *Theriogenology*, 226, 369-377. <https://doi.org/10.1016/j.theriogenology.2024.06.032>
- Diezma-Díaz, C., Jiménez-Meléndez, A., Re, M. T., Ferre, I., Ferreras, M, C., Gutiérrez-Expósito, D., Rojo-Montejo, S., Román-Trufero, A., Benavides-Silván, J., García-Lunar, P., Calleja-Bueno, L., Blanco-Murcia, J., Osoro, K., Ortega-Mora, L. M. & Álvarez-García, G. (2018). Effect of parasite dose and host age on the infection with *Besnoitia besnoiti* tachyzoites in cattle. *Transboundary and Emerging Diseases*, 00, 1-12.
- Diezma-Díaz, C., Tabanera, E., Ferre, I., Pizarro-Díaz, M., González-Huecas, M., Blanco-Murcia, J., Ortega-Mora, L.M. & Álvarez-García, G. (2020). Histological findings in experimentally infected male calves with chronic besnoitiosis. *Veterinary Parasitology*, 281, 109120.
- Dubey, J.P., van Wilpe, E., Blignaut, D.J.C., Schares, G. & Williams, J. H. (2013). Development of Early Tissue Cysts and Associated Pathology of *Besnoitia besnoiti* in a Naturally Infected Bull (*Bos taurus*) from South Africa. *Journal of Parasitology*, 99, 459-466.
- Đuračka, M., Belić, L., Tokárová, K., Žiarovská, J., Kačaniová, M., Lukáč, N. & Tvrdá, E. (2021). Bacterial communities in bovine ejaculates and their impact on the semen quality. *Systems biology in reproductive medicine*, 67(6), 438-449.
- Esteban-Gil, A., Jacquiet, P., Florentin, S., Decuadin, A., Berthelot, X., Ronsin, P., Grisez, C., Prevot, F., Alzieu, J.P., Marois, M., Corboz, N., Peglion, M., Vilardell, C., Liénard, E., Bouhsira, E., Castillo, J.A., Franc, M. & Picard-Hagen, N. (2016). Does bovine besnoitiosis affect the sexual function on chronically infected bulls?. *Theriogenology*, 86(5), 1325-1332.
- Fiebig, A., Vrentas, C.E., Le, T. & Crosson, S. (2021). Quantification of *Brucella abortus* population structure in a natural host. *PNAS*, 118, e2023500118 <https://doi.org/10.1073/pnas.2023500118>
- Ferrer, M.S., Palomares, R., Heins, B., Xavier, P., Fyke, H., Hurley, D.J. & Gordon, J. (2024). Analytical and clinical validation of diagnostic tests the detection of leucospermia in beef bulls. *Theriogenology*, 230, 46-53.
- Gajdács, M. & Urbán, E. (2020). The pathogenic role of Actinomyces spp. and related organisms in genitourinary infections: discoveries in the new, modern diagnostic era. *Antibiotics*, 9(8), 524.
- Giordani, F., Morrison, L. J., Rowan, T. G., De Koning, H. P. & Barrett, M.P. (2016). The animal trypanosomiasis and their chemotherapy: a review. *Parasitology*, 143, 1862-1889.
- Givens, M.D. (2018). Review: Risks of disease transmission through semen in cattle. *Animal*, 12(s1), s165-s171.
- Gómes, N. L., Chetty, T., Jorgensen, A. & Mitchell, R. T. (2020). Disorders of sex development-novel regulators, impacts on fertility, and options for fertility preservation. *International Journal of Molecular Science*, 21(7): 2282. <https://doi.org/10.3390/ijms21072282>.
- Gonzaga-Aivar, H., Escorcia-Reynoso, M., Delgado-Souto, S., Núñez-Martínez, G., Talavera-Mendoza, O., Martínez-Villalobos, N., Millán-Orozco, J. & Bottini-Luzardo, M. (2021). Estudio preliminar del efecto del consumo de metales pesados en el desarrollo e histología testicular del macho cabrío (*Capra hircus*). *Revista de Toxicología*, 38, 98-102.
- Grandjean-Lapierre, S., Thiberville, S. D., Fellag, M., Eghazarian, C., Bouzid, F., Gavril, C. & Drancourt, M. (2018). Recurrent bilateral

- Mycobacterium bovis* necrotizing epididymitis: a case report. *BMC Research Notes*, 11, 1-5.
- Harrison, T., Chaney, E.M., Brand, K.J., Ault-Seay, T.B., Schneider, L.G., Strickland, L.G., Schrick, F.N. & McLean, K.J. (2022). The effects of differing nutritional levels and body condition score on scrotal circumference, motility, and morphology of bovine sperm. *Translational Animal Science*, 6: 1-7. <https://doi.org/10.1093/tas/txaco01>
- Ivanov, A., Ignatev, V., Andreeva, A., Nikolaeva, O. & Ilyasova, Z. (2021). Opportunistic microorganisms in the etiology of nonspecific andrological diseases of cattle and comparative effectiveness of antibacterial drugs. *Advances in Animal and Veterinary Sciences*, 9(9), 1334-1341.
- Jibril, A., Ate, I.U., Rekwot, P.I. & Osuhor, C.U. (2011). Effect of graded levels and sources of protein on scrotal circumference and semen profile of Yankasa rams. *Sokoto Journal of Veterinary Sciences*, 9(1), 22-27.
- Kouamo, L. & Egbe Eta, L. (2021). Prevalence and associated risk factors of genital abnormalities in bulls slaughtered at the SODEPA industrial abattoir, Douala, Cameroon. *Journal of Infertility and Reproductive Biology*, 9, 136-141. [http://doi.org/10.47277/JIRB/9\(4\)/136](http://doi.org/10.47277/JIRB/9(4)/136)
- Kozioł, J. & Palmer, C. (2023). Pathophysiology, diagnosis, and management of testicular degeneration in the bull. *Clinical Theriogenology*, 15: 3-7 <https://doi.org/10.58292/CT.v15.971>
- López-Álvarez, A. M., Millán-Orozco, J., Millán-Orozco, J., Martínez-Millán, A., Bottini-Luzardo, M. B., de la Cruz-González, V. G. & Mosqueda, J., (2024). Detección serológica de anticuerpos anti-*Neospora caninum* con una prueba de ELISA competitiva en vacas Holstein-Friesian (*Bos taurus taurus*) con antecedentes de aborto en la Comarca Lagunera. LIX Reunión Nacional de Investigación Pecuaria, Aguascalientes, México; 23-24 Agosto 2024, pp: 464.
- Medel-Martínez, E., Saavedra-Jiménez, L. & Bottini-Luzardo, M. (2023). Testicular microlitiasis negatively affects sperm quality in bovine sires. *Studies in Environmental and Animal Sciences*, 4(1), 184-193.
- Morales, E., Trigo, F.J., Ibarra, F., Puente, E. & Santacruz, M. (2001). Neosporosis in Mexican Dairy Herds: Lesions and Immunohistochemical Detection of *Neospora caninum* in Fetuses. *Journal of Comparative Pathology*, 125, 58-63.
- Morán, P., Pérez, S.E., Odeón, A.C. & Verna, A.E. (2015). Herpesvirus bovino 4 (BoHV-4): aspectos generales de su biología y situación en la República Argentina. *Revista Argentina de Microbiología*, 47(2), 155-166.
- Neves, H. H.R., Vargas, G., Brito, L. F., Schenkel, F. S., Albuquerque, L.G. & Carvalheiro, R. (2019) Genetic and genomic analyses of testicular hypoplasia in Nelore cattle. *PLOS ONE* 14(1): e0211159. <https://doi.org/10.1371/journal.pone.0211159>
- Newcomer, B.W., Toohey-Kurth, K., Zhang, Y., Brodersen, B.W., Shonda Marley, M., Joiner, K.S., Zhang, Y., Galik, P.K., Riddell, K.P. & Givens, M.D. (2014). Laboratory diagnosis and transmissibility of bovine viral diarrhoea virus from a bull with a persistent testicular infection. *Veterinary Microbiology*, 170 (3-4), 246-257.
- Niranjan, S.K., Bishnoi, S., Godara, R.R. & Jayakumar, S. (2024). Klinefelter (XXY) syndrome in Sahiwal cattle: Distinguishable physical traits for early detection in field condition. *Journal of Livestock Biodiversity*, 10(1).
- Orlando, D. R., Costa, R. C., Soares, B. A., Oliveira, N. S., Nascimento, L. C., Peconick, A. P., & Varaschin, M. S. (2013). Neosporacanium abortions in cattle in southern Minas Gerais, Brazil. *Pesquisa Veterinária Brasileira*, 33, 1332-1338.
- Pichardo-Matamoros, D., Sevilla, F., Elizondo-Salazar, J., Jiménez-Sánchez, C., Roldan, E.R.S., Soler, C., Gacem, S. & Valverde, A. (2023). Exploration of semen quality analyzed by casa-mot systems of brahman bulls infected with BLV and BHV-1. *Scientific Reports*, 13, 186. <https://doi.org/10.1038/s41598-023-45981-9>
- Poester, F. P., Samartino, L. E. & Santos, R. L. (2013). Pathogenesis and pathobiology of brucellosis in livestock. *Revue Scientifique et Technique*, 32(1), 105-115.
- Puggioni, G., Pintus, D., Melzi, E., Meloni, G., Rocchigiani, A.M., Maestrale, C., Manunta, D., Savini, G., Dattena, M., Oggiano, A., Palmarini, M. & Ligios, C. (2018). Testicular degeneration and infertility following arbovirus infection. *Journal of Virology*, 92, (19), 1- 17.
- Rahman A., M., Lee, C.N. & Mishra, B. (2022). Adverse effects of phytoestrogens on mammalian reproductive health. *Veterinary Medicine and Animal Sciences*, 10, 1. <https://doi.org/10.7243/2054-3425-10-1>.
- Rekwot, P.I., Oyepide, E.O. Akerejola, O.O., Kumi-Diaka, J. & Umoh, J.E. (1987). The effect of protein intake on the onset of puberty in Bunaji and Friesian x Bunaji crossbred bulls in Nigeria. *Theriogenology*, 28, (4), 427-434.
- Ribeiro, C. M., Falleiros, M. B., Bicudo, S. D., Araujo Júnior, J. P., Golim, M. A., Silva Filho, F.C., Padovani, C. R. & Modolo, J.R. (2010). *Trichomonas foetus* extracellular products decrease progressive motility of bull sperm. *Theriogenology*, 73, 64-70.
- Rodriguez, S., Florins, A., Gillet, N., Brogniez, A., Sánchez-Alcaraz, M.T., Boxis, M., Boulanger, F., Gutierrez, G., Trono, K., Alvarez, I., Vagnoni, L. & Willems, L. (2011). Preventive and Therapeutic Strategies for Bovine Leukemia Virus: Lessons for HTLV. *MDPI*, 3(7), 1210-1218.
- Salvador, D.F. & Salvador S.C. (2021). Testicular hypoplasia in cattle: causes and consequences. *Ciência Animal*, 31 (1), 67-69.
- Santana, O.I., Cruz-Vázquez, C., Medina-Esparza, L., Ramos-Parra, M., Castellanos-Morales, C. & Quezada-Gallardo, D. (2010). *Neospora caninum*: Detección de ADN en sangre durante la primera gestación de vaquillas infectadas naturalmente. *Veterinaria México*, 41, 131-137.
- Silva, D.C., Piagentini, M., Dantas, A., Codognoto, M.V., Claro, M.M. & Oba, E. (2019). Importância do uso de minerais na dieta de bovinos reprodutores. *Veterinária e Zootecnia*, 25, 38-52. <https://rvz.emnuvens.com.br/rvz/issue/view/163/3>
- Souza, W.J., Nascente, F.C., Malaquias, J.V., Sereno, J.R.B., Viana, E.F., Silva, C.G. & Martins, C.F. (2018). Herpesvírus bovino tipo 1 (BoHV-1): método de diagnóstico e sua influencia na qualidade espermática em touros infectados experimentalmente. *Arquivo Brasileiro Medicina Veterinária. Zootecnia*, 70 (4). <https://doi.org/10.1590/1678-4162-10229>
- Tung, C. & Suarez, S. (2021). Co-Adaptation of Physical Attributes of the Mammalian Female Reproductive Tract and Sperm to Facilitate Fertilization. *Cells*, 10 (6), 1297. <https://doi.org/10.3390/cells10061297>
- Uyar, Ahment., Uslu, B.A. & Yurdakul, I. (2019). Evaluation on the histopathology of testes anomalies in the bulls slaughtered at the city of Van. *Dicle Üniversitesi Veteriner Fakültesi Dergisi*, 30-36.
- Veenakumari, L. & Sridevi, C. (2017). Actinomycosis in histopathology: Review of literature. *International Archives of Integrated Medicine*, 4(9),

195-206.

- Williams, H.J., Revells, S.G., Scholes, S. F. E., Courtenay, A. E. & Smith, R. F. (2010). Clinical, ultrasonographic and pathological findings in a bull with segmental aplasia of the mesonephric duct. *Reproduction in domestic animals*, 45: e212-e216. <https://doi.org/10.1111/j.1439-0531.2009.01543.x>
- Yurrita, S.C. (2016). Effects of dietary phytoestrogens on testicular growth and semen quality characteristics in developing Angus bulls *Journal of Animal Science*, 94, E-Suppl.: 606 <https://doi.org/10.2527/jam2016-1256>.
- Zhou, E., Silva, L. M., Conejeros, I., Velásquez, Z. D., Hirz, M., Gärtner, U., & Hermosilla, C. (2020). *Besnoitia besnoiti* bradyzoite stages induce suicidal and rapid vital-NEtosis. *Parasitology*, 147(4), 401-409.